

# Direct Composite Resins: Case Report

By Luis Guilherme Sensi, DDS, MS, PhD, Howard E. Strassler, DMD, William Webley and Robert C. Margeas, DDS

Layering of composite resins with different shades of dentins and enamels, have been proposed by numerous companies in the last decade. Many companies offer over 20 different shades of composites, which can sometimes make the process of choosing the right material very difficult. Kerr Corporation (Orange, CA) has recently introduced Herculite® Ultra as a mono-layering technique for a simple, effective way to restore teeth without complicated layering. The material comes in 11 different shades, 9 being enamels and 2 dentins. There are many practices that cannot afford to take the time to use multiple shades of composites due to the remuneration they are receiving for the procedure. Herculite Ultra has a chameleon effect due to their unique Point 4 filler and opalescent agent that helps blend the material to the surrounding teeth without having to use more than just one shade of enamel. This saves time and increases practice profitability. The material does not slump and is easily sculpted to place. Herculite Ultra's polishability and gloss retention is impressive for not being a microfill. Herculite Ultra's enamels are a bit more opaque than its XRV predecessor. This was sometimes a problem with XRV being too translucent.

Anatomical form must also be followed in order to replicate a natural tooth. One of the advantages of a direct resin restoration over a porcelain restoration is that the clinician is able to maintain control and customize the materials throughout the procedure.

Finishing and polishing the restoration is fundamental to achieving a beautiful final aesthetic result, and is paramount to maintaining the restoration over several years.

In fractures of teeth, the extent of the trauma must be assessed clinically and radiographically, before treatment is rendered. If the fracture is too large for a direct composite

restoration, than an indirect restoration could be used. It is very difficult to match a single anterior tooth. The technique of using direct resin as a restorative material, is an acquired skill, and requires practice to develop outstanding clinical results. The following procedure, describes a process in which a single layer of A1 enamel Herculite Ultra was used to restore mesial fractures of two central incisors.

A 32-year-old patient presented to the office with a mesial incisal fracture of the central incisors (Figure 1). A bevel was placed on the facial with a flame shaped diamond bur (Brasseler USA, Savannah, GA) and an approximate 1.5-mm bevel/chamfer on the lingual. Due to its ability to minimize the potential of microleakage and enhance bond strength to dentin and enamel, the "total-etch" technique was utilized. The right central incisor was etched for 15 seconds using 35% phosphoric acid gel (Figure 2). A clear matrix band was used to prevent the acid from contacting the adjacent tooth. This would be left in, until the bonding agent and first layer of composite was applied. The tooth was rinsed for 15 seconds and lightly air-dried, but not enough to desiccate the tooth. A dentin bonding agent was applied and light cured. The first layer of Herculite Ultra A1 was applied and the matrix strip was used to form the lingual (Figure 3). Another layer of Herculite Ultra A1 was placed and light cured for 20 seconds (Figure 4). A final layer of Herculite Ultra A1 was placed and slightly over built to allow for finishing and polishing (Figure 5). Light curing for 20 seconds was done following each increment and a final cure of 40 seconds was done after the last increment. The restoration was contoured and only the interproximal was polished to a higher glaze so the next restoration to be completed would not adhere to the first restoration.

The same procedure was done with the second restoration. The matrix band was placed, the tooth was etched, bonded and the first layer of Herculite Ultra A1 was placed. (Figure 6).

Another layer was placed and the matrix band was used to pull the material to the lingual and light cured for 40 seconds (Figure 7). Initial contouring was started using an OS1 bur (Brasseler USA) on the lingual. This allowed the creation of the proper lingual contour. An ET6 bur (Brasseler USA) was used to create an invisible margin and allow the composite to disappear into the tooth; the motion is from composite to tooth structure. Discs were used to create a highly polished restoration and to prevent future marginal leakage or white lines. Proper finishing and polishing will allow the patient to maintain the restorations for several years. The final restoration shows a highly polished and chameleon like effect using one shade of Herculite Ultra (Figure 8).

## References

1. Baratieri LN, Ritter AV, Perdigao J, Fillippe LA. Direct posterior composite resin restorations: current concepts for the technique. *Pract Periodontics Aesthet Dent.* 1998;10(7):875-886.
2. Fortin D, Vargas MA. The spectrum of composites: new techniques and materials. *J Am Dent Assoc.* 2000;131:26S-30S.
3. Cheung GS. Reducing marginal leakage of posterior composite resin restorations: a review of clinical techniques. *J Prosthet Dent.* 1990;63(3):286-288.
4. Baratieri LN, Ritter AV, Perdigao J, Fillippe LA. Direct posterior composite resin restorations: current concepts for the technique. *Pract Periodontics Aesthet Dent.* 1998;10(7):875-886.

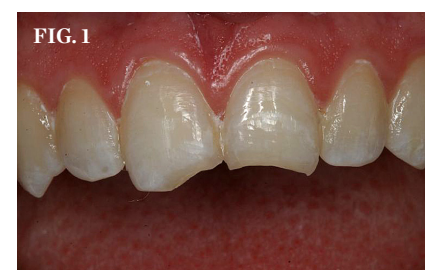**LUIS GUILHERME SENSI, DDS, MS, PHD**  
Assistant Professor  
Department of Endodontics, Prosthodontics and Operative Dentistry  
University of Maryland Dental School  
Baltimore, Maryland

**HOWARD E. STRASSLER, DMD**  
Professor and Director of Operative Dentistry  
Department of Endodontics, Prosthodontics and Operative Dentistry  
University of Maryland Dental School  
Baltimore, Maryland

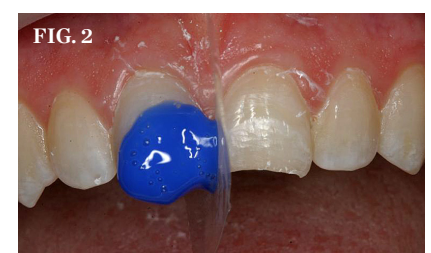
**WILLIAM WEBLEY**  
Undergraduate Dental Student  
University of Maryland Dental School  
Baltimore, Maryland

**ROBERT C. MARGEAS, DDS**  
Adjunct Professor  
Department of Operative Dentistry  
University of Iowa College of Dentistry  
Iowa City, Iowa

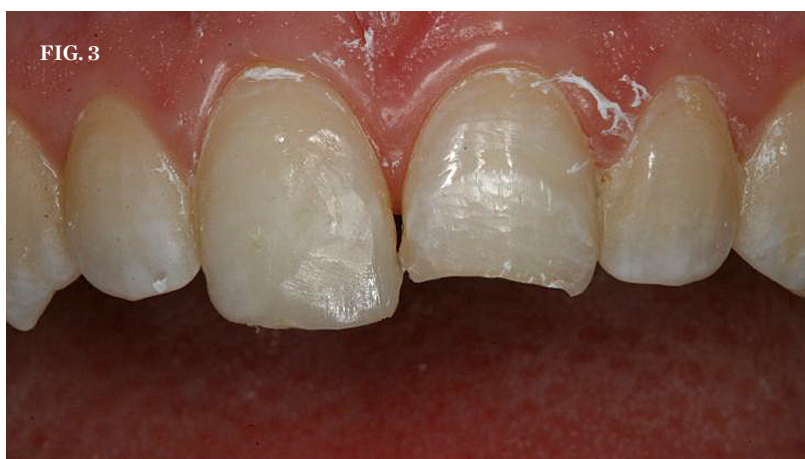Private Practice  
Des Moines, Iowa



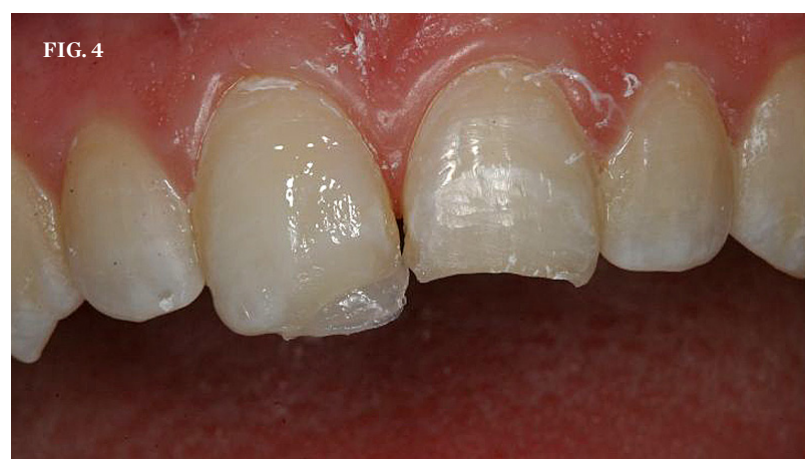(1.) Mesial incisal fracture of the central incisors.



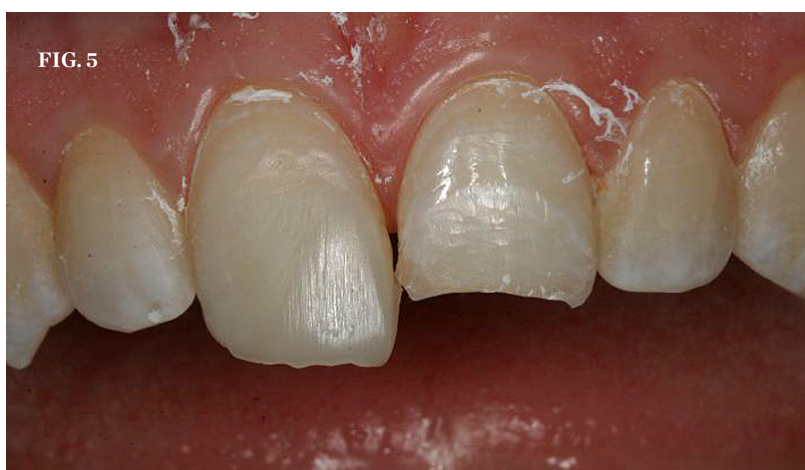(2.) Etching with 35% phosphoric acid gel.



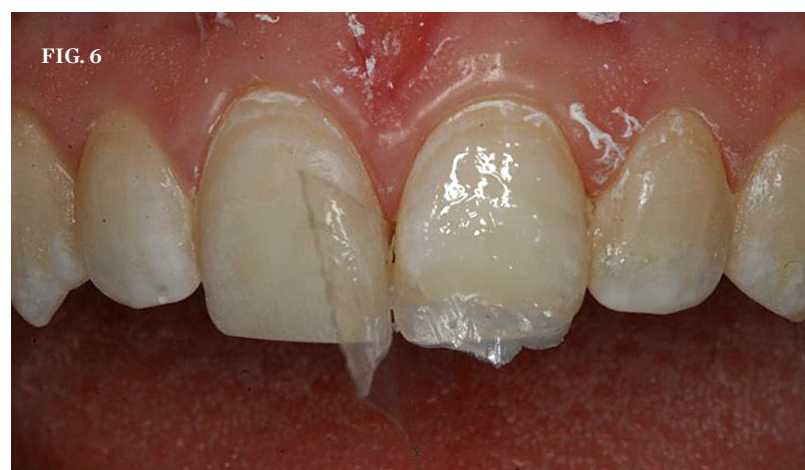(3.) Application of initial layer of Herculite Ultra A1 to right central incisor.



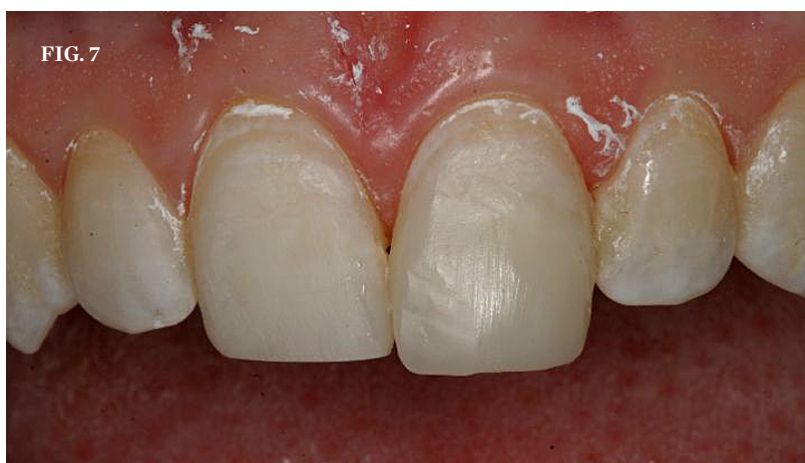(4.) A second layer of Herculite Ultra A1 placed and light cured.



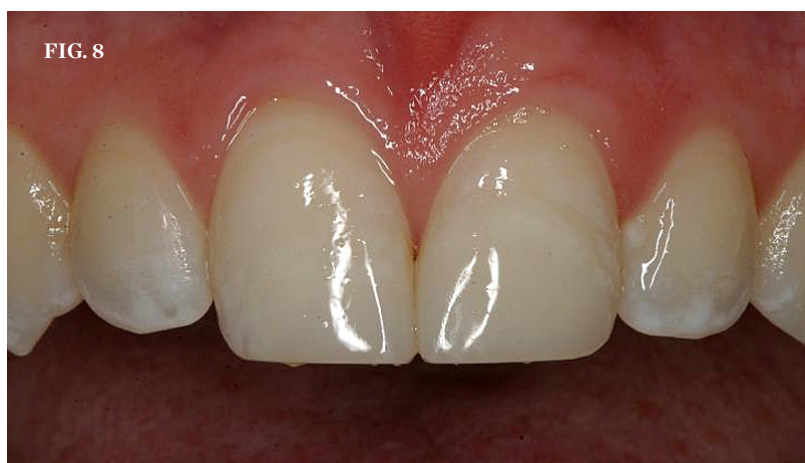(5.) Final layer of Herculite Ultra A1 placed and light cured. Note the slight build-over to allow for finishing and polishing.



(6.) First layer of Herculite Ultra A1 applied to prepared left central incisor.



(7.) Second layer of Herculite Ultra A1 placed and light cured.



(8.) The final restoration.